

## Mutations in coenzyme Q<sub>10</sub> biosynthetic genes

Salvatore DiMauro, ... , Catarina M. Quinzii, Michio Hirano

*J Clin Invest.* 2007;117(3):587-589. <https://doi.org/10.1172/JCI31423>.

### Commentary

Although it was first described in 1989, our understanding of coenzyme Q<sub>10</sub> (CoQ<sub>10</sub>) deficiency is only now coming of age with the recent first description of the underlying molecular defects. The diverse clinical presentations, classifiable into four major syndromes, raise the question as to whether the deficiencies are primary or secondary. Recent studies, including the one by Mollet, Rötig, and colleagues reported in this issue of the *JCI*, document molecular defects in three of the nine genes required for CoQ<sub>10</sub> biosynthesis, all of which are associated with early and severe clinical presentations (see the related article beginning on page 765). It is anticipated that defects in the other six genes will cause similar early-onset encephalomyopathies. Awareness of CoQ<sub>10</sub> deficiency is important because individuals with primary or secondary variants may benefit from oral CoQ<sub>10</sub> supplementation.

**Find the latest version:**

<https://jci.me/31423/pdf>





# Mutations in coenzyme Q<sub>10</sub> biosynthetic genes

Salvatore DiMauro, Catarina M. Quinzii, and Michio Hirano

Department of Neurology, Columbia University Medical Center, New York, New York, USA.

**Although it was first described in 1989, our understanding of coenzyme Q<sub>10</sub> (CoQ<sub>10</sub>) deficiency is only now coming of age with the recent first description of the underlying molecular defects. The diverse clinical presentations, classifiable into four major syndromes, raise the question as to whether the deficiencies are primary or secondary. Recent studies, including the one by Mollet, Rötig, and colleagues reported in this issue of the *JCI*, document molecular defects in three of the nine genes required for CoQ<sub>10</sub> biosynthesis, all of which are associated with early and severe clinical presentations (see the related article beginning on page 765). It is anticipated that defects in the other six genes will cause similar early-onset encephalomyopathies. Awareness of CoQ<sub>10</sub> deficiency is important because individuals with primary or secondary variants may benefit from oral CoQ<sub>10</sub> supplementation.**

## The first patients

In 1989 Ogasahara et al. described the first patients with coenzyme Q<sub>10</sub> (CoQ<sub>10</sub>) deficiency, presumably of the primary form (1). After normal early development, two sisters developed exercise intolerance and slowly developed progressive weakness of axial and proximal limb muscles. Around age five, brain involvement was manifested by learning disability in both sisters, seizures in one, and cerebellar syndrome in the other. In addition, both individuals had episodes of myoglobinuria following seizures or intercurrent infections. Family history suggested an autosomal recessive mode of inheritance. Laboratory abnormalities included lactic acidosis, increased serum creatine kinase levels, and myopathic electromyography. Muscle biopsies showed the presence of ragged-red fibers (RRFs) and excessive accumulation of lipid droplets in type I fibers. The concentration of CoQ<sub>10</sub> was markedly decreased (about 5% of normal) in muscle from both patients but was normal in serum and cultured fibroblasts. It was concluded that the primary defect in this family probably involved a tissue-specific isozyme in the CoQ<sub>10</sub> synthetic pathway of muscle and brain. Although this study was published in a high-profile journal, the report was followed by a

remarkably long silence: the next publications on patients with the same clinical triad (mitochondrial myopathy, recurrent myoglobinuria, and CNS signs) and muscle CoQ<sub>10</sub> deficiency appeared 8 and 11 years later (2, 3). Notably, all patients improved remarkably with oral CoQ<sub>10</sub> supplementation.

## Infantile encephalomyopathy

In 2000, however, Rötig and coworkers reported a second and much more dramatic variant of CoQ<sub>10</sub> deficiency, which presented as an infantile mitochondrial encephalomyopathy with widespread CoQ<sub>10</sub> deficiency and, interestingly, nephrotic syndrome (not a common renal manifestation of respiratory chain defects) (4). This article was remarkable because it heralded the discovery of CoQ<sub>10</sub> biosynthetic defects, two of which were identified at the molecular level just a few months ago (5, 6). In the study by Mollet, Rötig, and colleagues in this issue of the *JCI*, additional gene defects have been identified and proven to have functional effects (7). In 2000, Rötig et al. (4) had reported three affected children in a sibship of four, who presented soon after birth with neurological symptoms, including nystagmus (an involuntary, rapid, rhythmic movement of the eyeball), optic atrophy, neurosensory hearing loss, ataxia, dystonia, and weakness. Nephrosis had been rapidly progressive in all three: one died of renal failure at eight years of age, and the other two required renal transplantation. Biochemical analyses in various tissues from those patients (as in samples from patients described by Mollet

et al. in this issue; ref. 7) showed defects of respiratory chain reactions requiring CoQ<sub>10</sub>, and the defects were corrected in vitro by addition of a CoQ<sub>10</sub> analog to the reaction mixtures. Having found that CoQ<sub>10</sub> was undetectable in fibroblasts from one patient, Rötig et al. documented that CoQ<sub>10</sub> biosynthesis (measured in terms of [<sup>3</sup>H]mevalonate incorporation into CoQ<sub>10</sub>) was, in fact, blocked. Suspecting a defect in decaprenyl diphosphate synthase, the authors sequenced *prenyl-diphosphate synthase, subunit 1 (PDSS1)*, which encodes the human ortholog of the yeast *COQ1* gene, in one patient but found no deleterious mutations. Another remarkable feature of this disorder was the dramatic response of the two surviving patients to CoQ<sub>10</sub> supplementation.

## The plot thickens

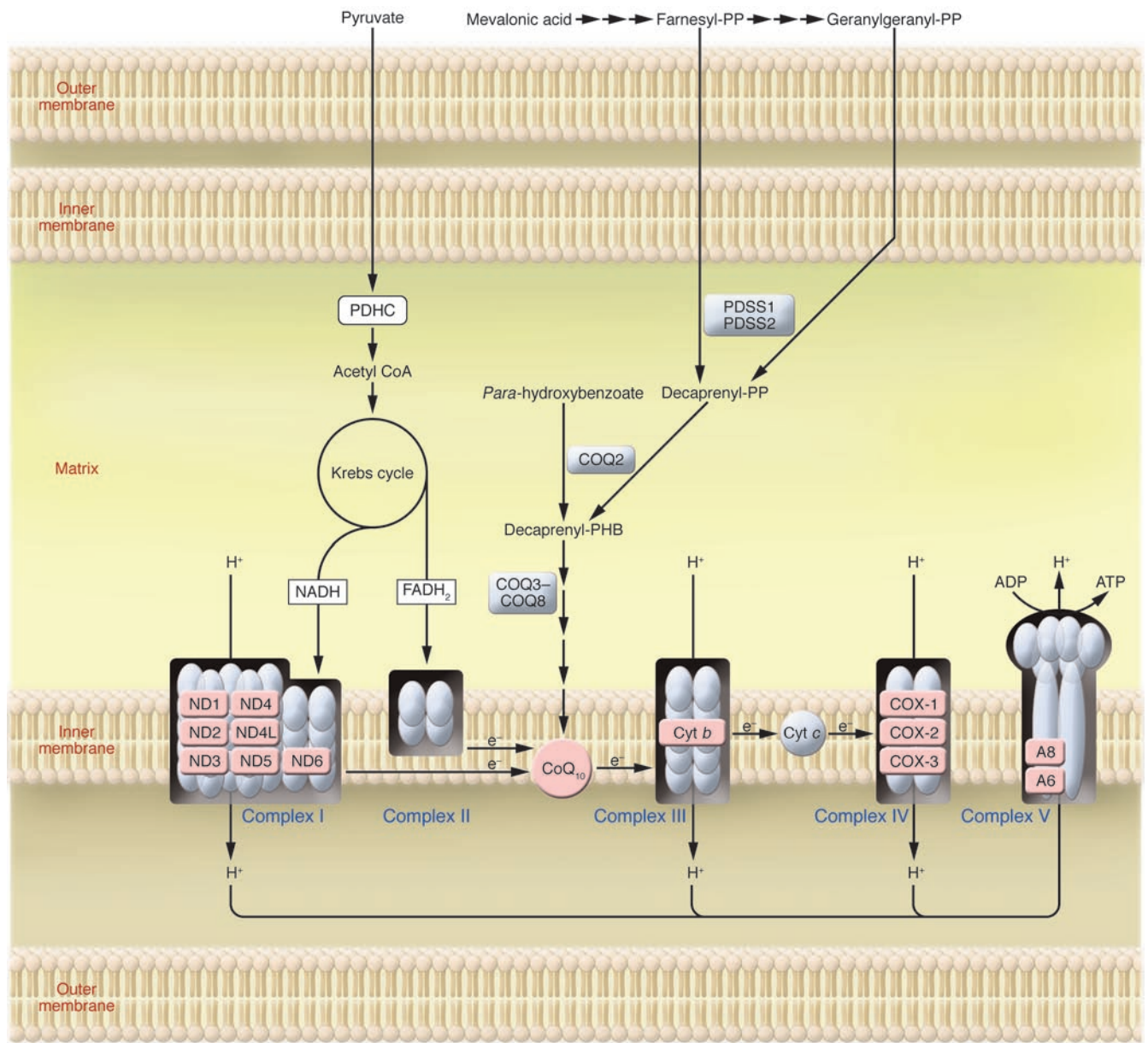
In the seven years separating Rötig's 2000 paper (4) from the study in this issue (7) from the same group, the plot of the CoQ<sub>10</sub> deficiency story has considerably thickened. While studying the second patient with the "myopathy-plus" syndrome (2), we found that one of our disease control muscle samples, belonging to a young man with cerebellar ataxia, also had a very low concentration of CoQ<sub>10</sub>. This serendipitous observation led us to study more than 100 patients, mostly children, with genetically undefined autosomal recessive spinocerebellar ataxia. We identified 21 patients who had, besides cerebellar ataxia and cerebellar atrophy, various neurological symptoms, including seizures, developmental delay, mental retardation, or spasticity (8–10). Muscle biopsies showed neither abnormal mitochondrial proliferation nor lipid storage, but CoQ<sub>10</sub> levels were markedly decreased in both muscle and cultured fibroblasts. Similar patients have been reported by others (11–13). All patients responded, at least to some extent, to CoQ<sub>10</sub> supplementation.

The latest development in the CoQ<sub>10</sub> deficiency saga has been the identification of patients with isolated myopathy, usually slowly progressive and involving proximal limb and axial muscles: muscle biopsies characteristically show mito-

**Nonstandard abbreviations used:** COQ2, OH-benzoate polyprenyltransferase; CoQ<sub>10</sub>, coenzyme Q<sub>10</sub>; *PDSS1*, *prenyldiphosphate synthase, subunit 1*; PHB, *para*-hydroxybenzoate; RRF, ragged-red fiber.

**Conflict of interest:** The authors have declared that no conflict of interest exists.

**Citation for this article:** *J. Clin. Invest.* 117:587–589 (2007). doi:10.1172/JCI31423.



**Figure 1**

CoQ<sub>10</sub> in mitochondrial metabolism. CoQ<sub>10</sub> is a vital component of the mitochondrial respiratory chain, where it shuttles electrons (e<sup>-</sup>) to complex III from complexes I and II. CoQ<sub>10</sub> biosynthesis occurs mainly in mitochondria. Decaprenyl diphosphate is synthesized by a heterotetrameric enzyme composed of PDSS1 and PDSS2 from mevalonate via farnesyl diphosphate and geranylgeranyl diphosphate and is attached to PHB by COQ2. Subsequently, at least 6 more COQ enzymes (COQ3–COQ8) catalyze methylation, decarboxylation, and hydroxylation reactions. A8, ATP synthase subunit 8; Cyt *b*, cytochrome *b*; FADH<sub>2</sub>, flavin adenine dinucleotide, reduced form; ND1–6, subunits 1–6 of NADH dehydrogenase; PP, diphosphate; PDHC, pyruvate dehydrogenase complex.

chondrial proliferation (as assessed by the observation of RRFs) and lipid storage (14, 15). Thus, it has become conventional to classify CoQ<sub>10</sub> deficiency into four major clinical categories: (a) myopathy with recurrent myoglobinuria and CNS involvement; (b) cerebellar ataxia with variable CNS involvement; (c) isolated myopathy; and (d) infantile mitochondri-

al encephalomyopathy. Because CoQ<sub>10</sub> in humans is almost completely synthesized endogenously, it has been assumed that these diverse syndromes are all due to primary CoQ<sub>10</sub> deficiency, and it has become commonplace to attribute the different clinical phenotype to blocks at different levels in the complex biosynthetic pathway of CoQ<sub>10</sub> (see Figure 1 in the article

by Mollet et al.; ref. 7). In this pathway, decaprenyl diphosphate is synthesized from mevalonate via farnesyl diphosphate (which is also a precursor of cholesterol, steroids, and farnesylated proteins) and is attached to the *para*-hydroxybenzoate (PHB) ring by OH-benzoate polyprenyltransferase (COQ2). However, after this condensation reaction, at least six more



COQ enzymes, catalyzing methylation, decarboxylation, and hydroxylation reactions, are needed to produce functional CoQ<sub>10</sub> (16) (Figure 1).

### CoQ10 deficiency: primary or secondary?

The central question in the burgeoning field of CoQ<sub>10</sub> deficiency is whether different clinical variants of the disease can all be ascribed to different biosynthetic errors or, alternatively, whether they encompass both primary and secondary forms of CoQ<sub>10</sub> deficiency. We now have experimental evidence that the second hypothesis is correct. Analysis of genome-wide microsatellite markers in a family with the ataxic variant of CoQ<sub>10</sub> deficiency suggested linkage of the disease to chromosome 9p13 and led to the identification in all three affected siblings of a homozygous mutation in the *aprataxin* (*APT*X) gene that causes ataxia oculomotor apraxia type 1 (AOA1) (17). Although the relationship between aprataxin, which is involved in nuclear DNA single-strand break repair, and CoQ<sub>10</sub> homeostasis remains to be clarified, this finding suggested that patients with the ataxic form of CoQ<sub>10</sub> deficiency should be examined for other gene defects causing autosomal recessive cerebellar ataxias (18). Metabolic defects in the mitochondrial respiratory chain or in other mitochondrial metabolic pathways may also result in CoQ<sub>10</sub> deficiency, although a study of 25 patients with mitochondrial encephalomyopathies, mostly due to mutations in mitochondrial DNA, showed a variable and, on average, mild (24%) decrease in muscle CoQ<sub>10</sub> level (19).

### Defects of CoQ<sub>10</sub> biosynthesis

On the other hand, three recent articles, including the present one by Mollet et al. (5–7), have documented the existence of primary CoQ<sub>10</sub> deficiency. Not too surprisingly, these biosynthetic defects have been associated with the earliest and most severe variant of CoQ<sub>10</sub> deficiency, infantile mitochondrial encephalomyopathy. More surprising, and more difficult to explain, is the clinical heterogeneity that is already emerging even within this group of disorders. For example, the two siblings examined in the current study with mutations in the first subunit of COQ1, PDSS1 (7), had a much milder phenotype (at the time of publication, they were 14 and 22 years of age, with obesity, hearing loss, optic atrophy, valvulopathy, and mild mental retardation) than the infant with

mutations in PDSS2, who was hypotonic at birth and died at 8 months of age after developing seizures, recurrent vomiting, cortical blindness, severe nephrosis, and the neuroradiological features of Leigh syndrome (6). Unfortunately, we have not been given any information on the neuro-radiology of the siblings with mutations in PDSS1: this would have been interesting, because in 2002 Van Maldergem et al. reported two sisters in their thirties with CoQ<sub>10</sub> deficiency and lifelong histories of encephalopathy, growth retardation, ataxia, deafness, mental retardation, lactic acidosis, and increased MRI signals in the caudate nucleus and putamen (20): they may also have had mutations in PDSS1, and this might still be tested. In view of the rather striking response of these women to CoQ<sub>10</sub> supplementation, it is surprising that CoQ<sub>10</sub> was not given by Mollet et al. to their patients, but perhaps this may still be attempted.

The patients with mutations in COQ2 had in common early-onset nephrosis and encephalopathy, but the infants homozygous for the Y297C mutation responded dramatically to CoQ<sub>10</sub> supplementation (5, 21), whereas those with the single-base-pair frameshift deletion died at 1 and 12 days (7). On the other hand, there are striking clinical similarities between the family with the Y297C mutation in COQ2 (5) and that reported by Rötig et al. in 2000 (4), including the severe nephrosis and the therapeutic effect of oral CoQ<sub>10</sub> supplementation. It would be interesting to see whether the patients reported by Rötig et al. also harbored mutations in COQ2.

### COQ genes: six to go

In summary, primary and secondary CoQ<sub>10</sub> deficiency have belatedly taken center stage in clinical research. Of the nine genes presumably involved in CoQ<sub>10</sub> biosynthesis and suspected of causing primary CoQ<sub>10</sub> deficiency, three — PDSS1, PDSS2, and COQ2 — have been found guilty. There is good reason to believe that mutations in the six genes still at large may soon be found to underlie human diseases. The paper by Mollet and Rötig (7) should serve as a wake-up call for clinicians confronted with early-onset mitochondrial encephalomyopathies, especially if associated with glomerulonephrosis. The need for research is made more urgent by the fact that some of these patients may be helped and even saved by timely administration of high-dose CoQ<sub>10</sub>.

Address correspondence to: Salvatore DiMauro, 4-420 College of Physicians & Surgeons, 630 West 168th Street, New York, New York 10032, USA. Phone: (212) 305-1662; Fax: (212) 305-3986; E-mail: sd12@columbia.edu.

1. Ogasahara, S., Engel, A.G., Frens, D., and Mack, D. 1989. Muscle coenzyme Q deficiency in familial mitochondrial encephalomyopathy. *Proc. Nat. Acad. Sci. U. S. A.* **86**:2379–2382.
2. Sobreira, C., et al. 1997. Mitochondrial encephalomyopathy with coenzyme Q10 deficiency. *Neurology*. **48**:1238–1243.
3. Di Giovanni, S., et al. 2001. Coenzyme Q10 reverses pathological phenotype and reduces apoptosis in familial CoQ10 deficiency. *Neurology*. **57**:515–518.
4. Rötig, A., et al. 2000. Quinone-responsive multiple respiratory-chain dysfunction due to widespread coenzyme Q10 deficiency. *Lancet*. **356**:391–395.
5. Quinzii, C., et al. 2006. A mutation in *para*-hydroxybenzoate-polyprenyl transferase (*COQ2*) causes primary coenzyme Q10 deficiency. *Am. J. Hum. Genet.* **78**:345–349.
6. López, L.C., et al. 2006. Leigh syndrome with nephropathy and CoQ10 deficiency due to decaprenyl diphosphate synthase subunit 2 (PDSS2) mutations. *Am. J. Hum. Genet.* **79**:1125–1129.
7. Mollet, J., et al. 2007. *Prenyldiphosphate synthase, subunit 1* (PDSS1) and *OH-benzoate polyprenyltransferase* (COQ2) mutations in ubiquinone deficiency and oxidative phosphorylation disorders. *J. Clin. Invest.* **117**:765–772. doi:10.1172/JCI29089.
8. Musumeci, O., et al. 2001. Familial cerebellar ataxia with muscle coenzyme Q10 deficiency. *Neurology*. **56**:849–855.
9. Lamperti, C., et al. 2003. Cerebellar ataxia and coenzyme Q10 deficiency. *Neurology*. **60**:1206–1208.
10. Gironi, M., et al. 2004. Late-onset cerebellar ataxia with hypogonadism and muscle coenzyme Q10 deficiency. *Neurology*. **62**:818–820.
11. Auré, K., et al. 2004. Progression despite replacement of a myopathic form of coenzyme Q10 defect. *Neurology*. **63**:727–729.
12. Boitier, E., et al. 1998. A case of mitochondrial encephalomyopathy associated with a muscle coenzyme Q10 deficiency. *J. Neurol. Sci.* **156**:41–46.
13. Artuch, R., et al. 2006. Cerebellar ataxia with coenzyme Q10 deficiency: diagnosis and follow-up after coenzyme Q10 supplementation. *J. Neurol. Sci.* **246**:153–158.
14. Lalani, S., et al. 2005. Isolated mitochondrial myopathy associated with muscle coenzyme Q10 deficiency. *Arch. Neurol.* **62**:317–320.
15. Horvath, R., et al. 2006. Coenzyme Q10 deficiency and isolated myopathy. *Neurology*. **66**:253–255.
16. Turunen, M., Olsson, J., and Dallner, G. 2004. Metabolism and function of coenzyme Q. *Biochim. Biophys. Acta.* **1660**:171–199.
17. Quinzii, C., et al. 2005. Coenzyme Q deficiency and cerebellar ataxia associated with an aprataxin mutation. *Neurology*. **64**:539–541.
18. Whaley, N.R., and Uitti, R.J. 2007. Inherited ataxias. In *Neurology and clinical neuroscience*. A.H.V. Schapira, editor. Mosby. Philadelphia, Pennsylvania, USA. 887–897.
19. Matsuoka, T., Maeda, H., Goto, Y., and Nonaka, I. 1992. Muscle coenzyme Q10 in mitochondrial encephalomyopathies. *Neuromusc. Disord.* **1**:443–447.
20. Van Maldergem, L., et al. 2002. Coenzyme Q-responsive Leigh's encephalopathy in two sisters. *Ann. Neurol.* **52**:750–754.
21. Salvati, L., et al. 2005. Infantile encephalomyopathy and nephropathy with CoQ10 deficiency: a CoQ10-responsive condition. *Neurology*. **65**:606–608.